

# What is the best approach to necrotizing enterocolitis?

## Qual é a melhor abordagem na enterocolite necrosante?

Wilma Lilia de Castro e Souza Silva<sup>1</sup>, Marcel Heibel<sup>2</sup>, Jorge Alberto Langbeck Ohana<sup>3</sup>, Janine Da Silva Lima Delilo<sup>4</sup>, Jorge Luiz De Mattos Zeve<sup>5</sup>, Timoteo Abrantes de Lacerda Almeida<sup>6</sup>, Luiz Martins Collaço<sup>1</sup>

### ABSTRACT

**Introduction:** Necrotizing enterocolitis is a serious disease that occurs in newborns, especially premature infants. It has a multifactorial cause, and its prognosis depends on early diagnosis to conduct timely intervention. Analysis of the cases indicates 3 main factors for its occurrence: extreme prematurity, low birth weight, and hypoxia causing tissue hypoperfusion. The modified Bell classification will indicate the treatment approach. Surgical intervention may be necessary in patients with intestinal perforation.

**Objective:** To verify its prevalence in neonatal ICUs and its correlation with prematurity, low birth weight, hypoxia, gender differences, and imaging tests that aid in classification or suggest tissue hypoxia.

**Method:** Observational, cross-sectional, retrospective study analyzing medical records of 26 patients diagnosed with necrotizing enterocolitis, focusing on clinical signs and symptoms associated with imaging findings to verify signs of acute abdomen. Sex, birth weight, gestational age and Apgar score at the end of the first minute were verified. Patients transferred from other services who did not have complete birth data were excluded.

**Results:** 26 patients of the 1,184 admitted to the neonatal ICU had necrotizing enterocolitis (2.19%). Of these, 22 had less than 37 weeks of gestational age (84%) and were classified as premature. Nine were over 1,500 g (34.6%). Apgar was below 7 at the end of the first minutes in 20 patients (76.92%), characterizing hypoxia at birth; one presented hypoxia after the 10th minute of life. There were 8 deaths (30%).

**Conclusion:** Necrotizing enterocolitis affects premature babies, mostly females, with low weight and with signs of hypoxia at birth; due to these factors, it presents severity with unfavorable outcome and high mortality. Early diagnosis is possible through clinical observation and imaging tests that, together, allow classification and decision-making.

**KEYWORDS:** Newborn. Prematurity. Necrotizing enterocolitis.

### Central Message

Necrotizing enterocolitis is a tissue disease. The full-term and healthy newborn, when receiving breast milk, initiates intestinal colonization, triggering a protective immune response against pathogenic organisms. Due to prematurity, there is a deficit in the development of immunity, which prevents defense against pathogenic bacteria in compromised intestinal tissue. It will be worse if the food provided is infant formula, without the immunological factors that are present in breast milk, and with the potential to cause allergies, in addition to being a substrate for bacterial development. It is the main gastrointestinal emergency that affects these small patients, and corresponds to between 1-8% of neonatal admissions to neonatal ICUs. This study analyzes the outcome of a group of patients with this infrequent disease.

### Prospect

Necrotizing enterocolitis can have a silent evolution, and a fulminant outcome; therefore, delay in diagnosis may lead to late management and intervention in very compromised tissue. Innovation and investment in safe, sensitive and specific diagnostic methods in relation to early signs brings great benefits. The use of bedside equipment has been widespread in several countries, as it allows assertive intervention in patients with high surgical risk, due to prematurity, low weight, and other complications subsequent to birth conditions or diseases that led to premature birth, such as cardiac malformation or neurological sequelae.

### RESUMO

**Introdução:** Enterocolite necrosante é doença grave que ocorre em recém-nascidos, principalmente prematuros. É de cause multifatorial, cujo prognóstico depende do diagnóstico precoce para conduzir intervenção oportuna. Análise dos casos apontam 3 principais fatores para sua ocorrência: prematuridade extrema, baixo peso ao nascer e hipóxia causando hipoperfusão tecidual. A classificação de Bell modificada indicará a conduta do tratamento. Pode ser necessária intervenção cirúrgica em pacientes que apresentem perfuração intestinal.

**Objetivo:** Verificar a sua prevalência em UTI neonatal e a correlação com prematuridade, baixo peso ao nascer, hipóxia, diferença entre sexos, e exames de imagem que auxiliem na classificação ou que sugirem hipóxia tecidual.

**Método:** Estudo observacional, transversal, retrospectivo analisando prontuários de 26 pacientes com diagnóstico de enterocolite necrosante, focando-se nos sinais e sintomas clínicos, associados aos achados de imagem para verificar sinais de abdome agudo. Verificou-se sexo, peso ao nascer, idade gestacional e Apgar no final do primeiro minuto. Foram excluídos os transferidos de outros serviços que não possuíam dados completos do nascimento.

**Resultado:** 26 pacientes dos 1184 internados na UTI neonatal apresentaram enterocolite necrosante (2,19%). Destes 22 tinham menos que 37 semanas de idade gestacional (84%), sendo classificados como prematuros. Nove tinham mais que 1.500 g, (34,6%). Apgar foi abaixo de 7 no final dos primeiros minutos em 20 pacientes (76,92%), caracterizando hipóxia ao nascer; um apresentou hipóxia após o 10º min de vida. Houve 8 óbitos (30%).

**Conclusão:** Enterocolite necrosante acomete bebês prematuros, mais do sexo feminino, com baixo peso e com sinais de hipóxia ao nascimento; devido estes fatores, apresenta gravidade com desfecho desfavorável e alta mortalidade. O diagnóstico precoce é possível através da observação clínica e exames de imagem que, em conjunto, permitem a classificação e tomada de decisão.

**PALAVRAS-CHAVE:** Recém-nascido. Prematuridade. Enterocolite necrosante.

<sup>1</sup>Instituto Presbiteriano Mackenzie, São Paulo, SP, Brazil;

<sup>2</sup>Department of Dermatology, Amazonas State University, Manaus, Amazonas, Brazil;

<sup>3</sup>Unimed Prime Hospital, Belém, Pará, Brazil;

<sup>4</sup>Acre State Hospital Foundation, Rio Branco, Acre, Brazil;

<sup>5</sup>Federal University of Tocantins, Palmas, Tocantins, Brazil;

<sup>6</sup>University of Miami, Miami, Florida, United States.

Conflict of interest: None | Funding: Partly by the Coordination for the Improvement of Higher Education Personnel - Brazil (CAPES) - Funding code 001 | Received: 29/07/2024 | Accepted: 22/10/2024 | Correspondence: [wilma.lilia@hotmail.com](mailto:wilma.lilia@hotmail.com) | Associate Editor: [Thelma Larocca Skare](mailto:Thelma.Larocca.Skare)

**How to cite:**

Silva WLCS, Heibel M, Ohana JAL, Delilo JS, Zeve JLM, Almeida TAL, Collaço LM. Qual é a melhor abordagem na enterocolite necrosante?. BioSCIENCE. 2024;82:e075

## INTRODUCTION

The neonatal intensive care unit (ICU) was initially developed in 1882 by the obstetrician Dr. Pierre Budin at the Charité Hospital in Paris, assisted by Madame Hery, assistant midwife. In 1914, Dr. Julius Hess, a pediatrician, organized the first center for premature newborns in Chicago at Michel Reese Hospital.<sup>1,2</sup> Subsequently, specialized care centers for premature newborns spread, accompanied by numerous advances in medicine, aiming at individualized care for critically ill newborns. Consequently, increasingly premature babies have survived, that is, with a gestational age below 36 weeks, and some with a gestational age of 25 weeks or less.<sup>3</sup> According to the Brazilian Society of Pediatrics and the Ministry of Health, ordinance no. 306, of March 28, 2016, the presence in the delivery room of a multiprofessional team trained to provide birth care is mandatory, up to minimal care, such as the humanization of diaper changes and the beginning of feeding.<sup>4</sup> The presence of equipment with greater resolution of priority needs and specialized training in the use of new technologies is also recommended. Specialized care is important in the first minutes of life, especially the greater the prematurity or the complexity of the complications associated with birth. However, it is important that this commitment to care remains during the entire period of hospitalization in the intensive care unit, which can last for months, until the baby reaches minimum weight for discharge, a period in which he will often be exposed to factors that can compromise his physical integrity.<sup>1</sup>

Necrotizing enterocolitis is a tissue disease. The full-term and healthy newborn, when receiving breast milk, initiates intestinal colonization, triggering a protective immune response against pathogenic organisms. Due to prematurity, there is a deficit in the development of immunity, which prevents defense against pathogenic bacteria in compromised intestinal tissue. It will be worse if the food provided is infant formula, without the immunological factors, which are present in breast milk, and with the potential to cause allergies, in addition to being a substrate for bacterial development. It is the main gastrointestinal emergency that affects these small patients, and corresponds to between 1-8% of neonatal admissions to neonatal ICUs.<sup>5</sup> The first signs of this disease date back to reports by Charles-Michel Billard, a French pediatrician, who described in 1823 a case of gangrenous enterocolitis in a newborn with infection, inflammation and necrosis of the gastrointestinal tract. Then, in 1888, Paltauf described 5 patients who died of peritonitis, and in 1953 Schmid and Quaiser used the term necrotizing enterocolitis for the first time.<sup>3</sup> According to Data SUS (2017), it affects 10% of premature newborns. Death can occur in 20%, and can reach 50% if there is a need for surgical intervention.<sup>6</sup> Necrotizing enterocolitis is characterized by initial systemic clinical symptoms such as pallor, tachycardia, tachypnea, fever, hypoactivity, and gastrointestinal signs such as abdominal distension, relief of loops, and pain on abdominal palpation, which will have repercussions on changes in laboratory and imaging tests.<sup>7</sup>

The study and knowledge of necrotizing enterocolitis is relevant in the hospital environment due to the high mortality among patients affected by it, which brings immeasurable emotional cost to the family. There is an increase in the length of stay in the neonatal ICU, short- and long-term sequelae, such as ileostomy and short bowel syndrome, and possible readmissions. Serial laboratory and imaging exams, procedures in the operating room, various treatments with medications and antibiotic therapy, as well as outpatient and palliative follow-up after discharge are performed.

The lack of data in the literature relating the patient's profile, comorbidities and the help of tests to contribute to the diagnosis of the disease, led these authors to develop the current research in the sense of a better understanding of the prevalence, correlation with prematurity, birth weight, hypoxia, difference between sexes and suggesting the tests to be used.

## METHOD

This is an observational, cross-sectional, retrospective study. The electronic medical records of 26 patients admitted to the neonatal ICU between January 2022 and December 2023 with suspected necrotizing enterocolitis were analyzed. It was submitted to the Human Research Ethics Committee and approved by opinion number HUEM 7.120.781 CAAE: 65601922.5.0000.0103. Those transferred to the hospital's neonatal ICU who had incomplete medical records and/or had difficulty accessing data were excluded.

The following parameters were analyzed from the medical records: gender, gestational age and birth weight, Apgar score in the first minute, and symptoms or signs that suggested necrotizing enterocolitis. Based on the signs, symptoms, and results of the complementary tests performed, the degree of necrotizing enterocolitis was classified using the modified Bell classification (Figure 1). The results of plain radiography and abdominal ultrasonography, echocardiogram and transfontanel ultrasonography were analyzed.

Abdominal ultrasounds looked for signs of distension of the loops, ascites and air in the portal system. The echocardiograms performed by pediatric cardiologists detected congenital cardiac malformations such as patent ductus arteriosus, atrial septal defect, ventricular septal defect, ventricular hypoplasia, coarctation of the aorta, situations that compromised blood flow and tissue oxygenation, being directly related to hypoxia - one of the causal factors of necrotizing enterocolitis.

Transfontanelle ultrasound was used to look for signs demonstrating hypoxic, ischemic or hemorrhagic brain lesions. The involvement of brain tissue may be a reflection of hypoxia at birth in conjunction with Apgar scores below 7, suggesting the possibility that hypoxia has occurred in another organ such as the intestine, and triggers necrotizing enterocolitis. The areas of brain injury produce seizures, successively compromising tissue perfusion. The records of the MV electronic medical records were transcribed into an Excel spreadsheet and analyzed.

## RESULT

During the study period, 1,184 patients were admitted to the neonatal ICU and 26 medical records (2.19%) were diagnosed with necrotizing enterocolitis. There were 15 females (58%) and 11 males (42%). Twenty-two (84%) were premature newborns with gestational age below 37 weeks using the Capurro method.

**TABLE 1** – Gestational age of patients diagnosed with necrotizing enterocolitis

Rating as gestational age	n	%
Term	4	15,3%
Late preterm	3	11,5%
Moderate preterm	2	7,6%
Very preterm	8	30,7%
Extreme preterm	9	34,6%

Regarding low birth weight, which is an important factor in relation to the development of necrotizing enterocolitis, it was predominant in those weighing less than 1000 g (Table 2).

**TABLE 2** – Distribution in relation to birth weight of those with necrotizing enterocolitis.

Birth weight	n	%
More than 1,500 g	9	34,6%
Between 1,000 and 1,500 g	5	19,2%
Less than 1,000 g	12	46,2%

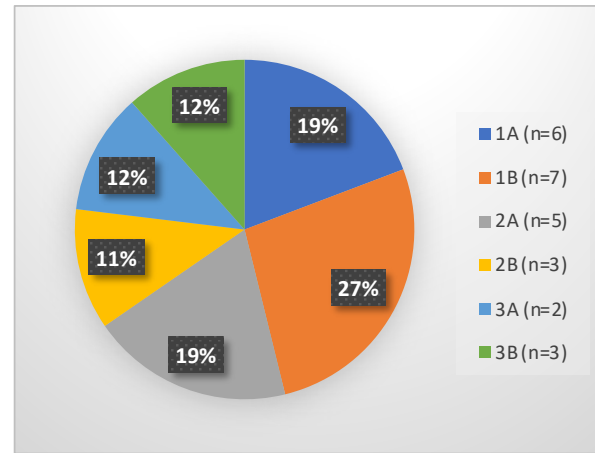
Apgar scores were observed at the end of the first minute of birth, and it was below 7 in 20 patients, showing

**TABLE 3** – Details of clinical and examination findings

	Capurro	Weight	Apgar	Sex	Diagnosis	Rx of abdomen	Echo abdomen	Cardio echo	Brain echo	Evolution
1	23 wk	525 g	2 and 5	F	ECN 2A	Pneumoperitoneum	Not performed	Lightweight HP Wide PCA	Hemorrhage	Death
2	32 wks	2035 g	5 and 8	F	ECN 1A	Normal	Normal	Normal	Normal	Clinical tto discharge
3	34 wks	1700 g	6 and 8	F	ECN 1A	Strap stretch	Ascites	Coarctation of the aorta		Death
4	28 wks	895 g	3 and 8	F	ECN 1A	Strap stretch	Strap stretch	Broad PCA	Hemorrhage	Ileostomy*
5	27 wks	930 g	3 and 8	F	ECN 2A	Strap stretch	Not performed	PCA Flow Bypass Mes	Hemorrhage	Clinical tto discharge
6	27 wks	800 g	5 and 8	F	ECN 1A	Strap stretch	Normal	PCA/HP/FOP	Hemorrhage	Death
7	39 wks	3220 g	2 and 4	M	ECN 3A	Strap stretch	Ascites	Normal	Normal	Death
8	34 wks	2000 g	2 and 3	F	ECN 3A	Normal	Ascites	Normal	Encephalomalacia	Palliative
9	23 wk	700 g	1 and 4	F	ECN 1B	Strap stretch	Bile Mud	PCA Flow Bypass Mes	Hemorrhage	Death
10	34 wks	1975 g	7 and 9	M	ECN 3B	Pneumoperitoneum	Normal	Normal	Hemorrhage	Surgical tto discharge
11	26 wks	730 g	1 and 4	F	ECN 1B	Strap stretch	Strap stretch	PCA w/ rebound	Leukomalacia	Palliative
12	30 wks	1625 g	5 and 9	M	ECN 3B	Pneumoperitoneum	Ascites	Normal	Normal	Surgical tto discharge
13	39 wks	3470 g	7 and 8	M	ECN 2B	Strap stretch	Normal	PCA/CIA/CIV/HP	Shadow Demon from down	Clinical tto discharge
14	26 wks	840 g	3 and 8	M	ECN 2A	Pneumatosis intest	Strap stretch	Broad PCA	Normal	Clinical tto discharge
15	26 wks	700 g	0 and 2	M	ECN 1A	Strap stretch	Normal	PCA w/ Reperc hemod	Hemorrhag/leucomal	High tto clin
16	38 wks	3210 g	3 and 7	F	ECN 1B	Strap stretch	Portal vein thrombosis	Hypoplasia VE/cia/pca	Normal	Death
17	28 wks	850 g	7 and 9	F	ECN 2B	Strap stretch	Strap Stretch	PCA w/ Reperc hemod	Hemorrhage	Ileostomy
18	32wk	1175 g	8 and 9	F	ECN 2B	Pneumoperitoneum	Ascites	Normal	Hemorrhage	Death
19	31 wk	1405 g	7 e 9	M	ECN 2A	Pneumatosis intest	Not realized	PCA w/ Reperc hemod	Hemorrhage	High tto clin
20	29 wks	1440 g	3 and 5	M	ECN 1B	Not realized	Strap Stretch	PCA without reperc hemod	Shadow Demon of patau	Paleative
21	37 wks	1400 g	6 and 9	M	ECN 3B	Pneumatosis intest	Normal	Total septoav and aorta defect	Shadow Demon of Edwards	Death
22	31 wks	1625 g	2 and -	M	ECN 1A	Strap stretch	Normal	Cia	Hemorrhage	High tto clin
23	27 wks	640 g	3 and 8	F	ECN 1B	Strap stretch	Normal	PCA without reperc hemod	Leukomalacia	High tto clin
24	27 wks	670 g	4 and 9	M	ECN 2A	Pneumatosis intest	Ascites	Moderate PCA	Hemorrhage	High tto clin
25	28 wks	860 g	4 and 8	F	ECN 1B	Strap stretch	Normal	PCA w/ Reperc hemod	Hemorrhage	High tto clin
26	29 wks	1190 g	8 and 9	F	ECN 1B	Strap stretch	Normal	Normal	Hemorrhage	High tto clin

hypoxia in 76.92%. One patient, despite being born with an 8/9 Apgar score and showing good vitality, presented apnea at 13 min of life, requiring cardiorespiratory resuscitation, with hypoxia and neurological sequelae during hospitalization.

Regarding the modified Bell classification of necrotizing enterocolitis, the 26 cases were distributed according to Figure.



**FIGURE** – Modified Bell classification in necrotizing enterocolitis.

The 26 patients fasted when they were hospitalized, received colostrum, breast milk, or pasteurized human milk when they were clinically stable. When signs of abdominal impairment appeared, such as abdominal distension or intestinal bleeding, everyone's diet was suspended and cautiously reintroduced as symptoms improved.

Regarding the examinations during the hospitalization period, there was an imaging evaluation with results that reflected the occurrence of hypoxia. Cerebral ultrasound in 22 (84.6%) presented an image compatible with germinal matrix or encephalomalaceal hemorrhage, being suggestive of sequelae of the brain tissue injury. On echocardiography, 19 (73%) had changes in cardiac morphology and repercussions on blood flow, resulting in a decrease in tissue perfusion.

Three patients (11.5%) were born with complex congenital malformations such as Down, Edwards, and Patau syndromes.

With regard to care and treatment, 3 (11.5%) were included in palliative care after discharge. Seven (26.9%) underwent surgical treatment, and 3 (11.5%) were discharged with ileostomy.

There were 8 deaths, representing 30% of the total sample.

## DISCUSSION

Necrotizing enterocolitis is a serious disease that affects children in general with the following profile: premature, low weight, with hypoxia at birth, or associated disease that causes hypoxia during hospitalization. It is a serious emergency among newborns hospitalized in the neonatal ICU.

The occurrence of necrotizing enterocolitis in this study reveals approximately the same data as those of Lima, de Souza and Ávila<sup>7</sup>, of 1-8%.<sup>7</sup> Of the 26 babies, 15 were girls (57.6%) and 11 were boys (42.33%).

Preterm infants with gestational age below 37 weeks were the most affected (84%). Vasques<sup>8</sup> states that the higher the prematurity, the greater the occurrence of necrotizing enterocolitis. Regarding this series, among infants under 28 weeks, extremely preterm infants, there were 9 cases of enterocolitis (34.6%), which is in agreement with a review conducted by Hachem et al.<sup>3</sup>

Low birth weight is a factor with a worse prognosis and occurred in 12 cases below 1,000 g (46.15%) almost half of all patients included.<sup>9</sup>

Twenty-one patients (80.7%) had hypoxia, 20 at birth with an Apgar score below 7 in the first minute and 1 with cardiorespiratory arrest after being transferred from the delivery room to the neonatal ICU, with 13 min of cardiorespiratory resuscitation. The analysis of the data corroborated what has been described in the literature, that hypoxia at birth is one of the contributing factors to the occurrence of necrotizing enterocolitis.<sup>5,7,9</sup>

It is important to observe the clinical signs because images may be initially non-existent, making clinical and/or surgical management expectant, despite the unfavorable evolution of the intestinal lesion. The image suggestive of severity resulting from intestinal perforation is intestinal pneumatosis, or air image in the portal vein that can be observed on abdominal radiographic or ultrasound study, and indicating an invasive but resolute approach, requiring several repetitions to ensure that pathognomonic findings of intestinal perforation do not go unnoticed.<sup>8,10</sup> There was one case of recurrence after discharge with acute abdomen on ultrasound, who

presented a sign of intestinal stenosis, probably scarring to necrotizing enterocolitis, which was not diagnosed in its severity, according to the pediatric surgery team.

Ultrasound for this diagnosis is the possibility of lower radiation in the follow-up of the evolution of the condition, instead of X-rays every 6/8 hours, according to the protocol proposed in the literature.<sup>11</sup>

Necrotizing enterocolitis may have a silent evolution and fulminant outcome; therefore, delay in diagnosis may lead to late management and intervention in very compromised tissue. Innovation and investment in safe, sensitive and specific diagnostic methods in relation to early signs brings great benefits.<sup>11</sup>

The use of bedside equipment with trained professionals has been widespread in several countries around the world, with great acceptance by neonatologists and pediatric surgeons, as it allows assertive intervention in patients with high surgical risk, due to prematurity, low weight, and other complications subsequent to birth conditions or diseases that led to premature birth, such as cardiac malformation or neurological sequelae.<sup>11</sup>

Three patients were readmitted after discharge from the neonatal ICU with an acute abdomen and intestinal stenosis causing obstruction was evidenced by ultrasound or laparotomy. These patients may have been affected by undiagnosed or even diagnosed necrotizing enterocolitis and submitted to clinical treatment with improvement without intestinal perforation or acute abdomen, resulting in intestinal stenosis.<sup>1,3,10</sup> Short bowel syndrome is a postoperative complication in patients with intestinal necrosis and perforation due to the removal of the affected intestinal portion. It will result in difficulty in absorbing nutrients necessary for development that was born with weight impairment.<sup>7,12</sup> There were 8 deaths (30%) from the disease,

Necrotizing enterocolitis leaves a wide range of questions, as there are several points to be elucidated in relation to its etiology, diagnosis, and treatment. Analyzing the causal factors reported as a whole, it was found that most of the affected babies were premature, with low birth weight, and with hypoxia at birth.

## CONCLUSION

The prevalence of necrotizing enterocolitis in the neonatal ICU was 2.19%. It affected more premature babies, and the higher the prematurity the occurrence. Low birth weight was also observed among newborns who developed it, and the lower the birth weight, the higher the number of cases. A higher occurrence was observed in babies with Apgar scores below 7 on the 5th. or who subsequently suffered hypoxia due to cardiorespiratory arrest. The number of cases was higher in girls. In the diagnosis, it was observed that the radiographic study of the abdomen and abdominal ultrasound were a priority. Imaging such as transfontanelle ultrasound, in turn, should be used to evaluate hypoxic brain injury and possibly hypoxia in other tissues, and echocardiography to verify the existence of cardiac malformations that led to intestinal hypoperfusion.

#### Authors' contributions

Conceptualization: Wilma Lilia de Castro e Souza Silva  
Research: Marcel Heibel, Timoteo Almeida  
Methodology: Jorge Alberto Langbeck Ohana  
Project administration: Janine da Silva Lima Delilo  
Writing (original draft): Jorge Luiz de Mattos Zeve  
Writing (proofreading and editing): Luiz Martins Collaço

## REFERENCES

1. MacDonald MG, Seshia MMK. *Avery Neonatology, Pathophysiology and Treatment of the Newborn*. 7th ed. Rio de Janeiro: Guanabara Koogan; 2018.
2. Rodrigues RG, Oliveira IC dos S. The beginnings of newborn care abroad and in Brazil: perspectives for nursing knowledge in neonatology (1870-1903). *Rev Eletrônica Enferm*. 2004; 6(2):286-91. <https://doi.org/10.5216/ree.v6i2.809>
3. Hachem AS, Lyra JC, Scarpa EC, Bentlin MR. Necrotizing enterocolitis: a literature review. *Resid Pediatr*. 2022; 12(3):1-7. <https://doi.org/10.25060/residpediatr-2022.v12n3-519>
4. Brazil. Ministry of Health - Health Care Secretariat, Department of Strategic Programmatic Actions. *Humanized care for low birth weight newborns: Kangaroo Method: technical manual*. 2nd ed. Brasília: Editora MS; 2013. 204 p.
5. Vieira MT, Lopes JM de A. Factors associated with necrotizing enterocolitis. *J Pediatr (Rio J)*. 2003; 79(72):159-64. <https://doi.org/10.1590/S0021-75572003000200011>
6. Feldens L, de Souza JCK, Fraga JC. There is an association between the location of the disease and gestational age at birth in newborns operated on for necrotizing enterocolitis. *J Pediatr (Rio J)*. 2018; 94(3):320-24. <https://doi.org/10.1016/j.jped.2017.06.010>
7. Lima SS, de Souza JIC, Ávila PE dos S. Necrotizing enterocolitis in a neonatal intensive care unit. *Rev Paranaense Med*. 2015; 29(2):63-8.
8. Vasques KDBR, Santos E de O, Aleixo NE. Neonatal necrotizing enterocolitis: case report and literature review. *Resid Pediatr*. 2023; 13(3):1-5. <https://doi.org/10.25060/residpediatr-2023.v13n3-567>
9. Vieira AA, David BBL, Lino RRG, Duarte L de B, Bueno AC. Evaluation of perinatal factors that interfere with the incidence of necrotizing enterocolitis in very low birth weight infants. *Rev Bras Ginecol Obstet*. 2013; 35(8):363-6. <https://doi.org/10.1590/S0100-72032013000800005>
10. de Oliveira ND, Myoshi MH. Advances in necrotizing enterocolitis. *J Pediatr (Rio J)*. 2005; 81(1 Suppl):S16-22. <https://doi.org/10.1590/S0021-75572005000200003>
11. Miranda FC, Sameshima YT, Deutsch AD, Warth AN, Francisco-Neto MJ, Funari MB de G. Ultrasonography in diagnosis of necrotizing enterocolitis. *Einstein*. 2009; 7(1):91-5.
12. Yikilmaz A, Hall NJ, Daneman A, Gerstle JT, Navarro OM, Moineddin R, et al. Prospective evaluation of the impact of sonography on the management and surgical intervention of neonates with necrotizing enterocolitis. *Pediatr Surg Int*. 2014; 30(12):1231-40. <https://doi.org/10.1007/s00383-014-3613-8>